

PATTERNS OF LARYNGEAL APRAXIA IN TWO PATIENTS WITH BROCA'S APHASIA¹

Philip Hoole, Heidrun Schröter-Morasch and Wolfram Ziegler

EKN Entwicklungsgruppe Klinische Neuropsychologie
Dachauer Straße 164
D-80992 Munich, Germany
hoole@phonetik.uni-muenchen.de

ABSTRACT

In this study the transillumination technique was applied to the study of laryngeal movements during speaking in two Broca's aphasics with apraxia of speech. In particular, laryngeal adductory and abductory gestures in the production of voiced and voiceless obstruents were analyzed. The two patients presented disturbances concerning movement shape, amplitude, and timing. Patient 1 had particular problems in the initiation of laryngeal adduction. These observations are compared to the patients' clinical patterns of apraxic speech and are discussed in the light of earlier studies of apraxic speech.

INTRODUCTION

One of the most remarkable clinical features characterizing the syndrome of apraxia of speech is that - unlike the dysarthrias - it usually has no "dysphonic" component. Some authors have reported observations of increased pitch in patients with Broca's aphasia, but these findings were attributed to psychological stress induced by the particular setting of a speech examination rather than to an apraxic disorder (Heeschen, Ryalls & Hagoort, 1988; Ryalls, 1984). Apart from this, the voice of apraxic speakers is typically not compromised by features like aberrant voice quality (but Ryalls & Scarfone, 1990), impaired pitch or loudness control, or vocal instability. Thus, the pathomechanism underlying apraxia of speech apparently spares the motor processes involved in the control of phonation. There are a few exceptions to this rule, among them reports of persisting "apraxic mutism" with a complete

inability to phonate voluntarily (e.g. Groswasser, Korn, Groswasser-Reider, I. and Solzi, 1988; Pineda & Ardila, 1992). However, these patients usually have bilateral lesions (for a review see Ziegler & Ackermann, 1994).

Despite the lack of dysphonic signs, however, laryngeal motor activity in apraxic speakers is not considered to be entirely undisturbed. Firstly, non-fluent aphasics are known to exhibit reduced F0-modulation, which is one component of their frequent clinical characterization as being dysprosodic (Gandour, Petty & Dardarananda, 1989; Danly & Shapiro, 1982). Secondly, analysis of F0 has revealed disturbance of normal tonal coarticulatory patterns for the tone-language Thai (Gandour, Potisuk, Ponglorpisit, Dechongit, Khunadorn & Boongird, 1996). Thirdly, perceptual descriptions of apraxic speech have stressed the frequent occurrence of phonetic and phonemic errors in the voiced-voiceless-dimension, often in the sense of a devoicing of voiced consonants (e.g. Odell, McNeil, Rosenbek & Hunter, 1990). Similarly, acoustic analyses have revealed aberrations in the voice onset times of plosives in both Broca's aphasia (Blumstein, Cooper, Goodglass, Statlender & Gottlieb (1980) and apraxia of speech (e.g. Itoh, Sasanuma, Tatsumi, Murakami, Fukusako & Suzuki, 1982; Ziegler, 1987; Hoit-Dalgaard, Murray & Kopp, 1983). The latter symptoms have usually been attributed to a disturbed temporal coordination of laryngeal and supralaryngeal movements, i.e. to an impairment of laryngeal gestures arising at the level of their interaction with other speech gestures. A most striking example of such a disintegration was communicated by Marshall, Gandour & Windsor (1988). These authors reported on a patient who demonstrated all signs of a severe apraxia of speech, but

¹Published in *Clinical Linguistics and Phonetics*, 1997, Vol. 11, No. 6, 429-442.

whose speech became almost entirely normal when he used an electrolarynx, i.e. when the degrees of freedom of his speech apparatus were critically reduced by keeping laryngeal activity constant. A similar interpretation might apply to a patient described by Ruff & Arbit, 1981, who, after a left frontal hemorrhage, was able to either phonate (i.e. hum melodies) or articulate without voice, but was unable to coordinate voice and articulation to produce normal speech.

These observations suggest that apraxic disorders of speech movements would not necessarily spare the laryngeal system, but would rather afflict the phasic activities of laryngeal posturing as they interact with articulation. However, evidence for this has so far been only indirect, i.e. exclusively based on perceptual and acoustic data. Direct observations of laryngeal movements during speaking in apraxic patients have not been reported so far.

For assessment of laryngeal gestures in running speech, particularly the devoicing gesture, the transillumination (photoelectroglottographic) technique has proved very useful. Moreover, it can be easily combined with laryngeal fiberscopy (Löfqvist & Yoshioka, 1980; Hoole, in press, b) without additional discomfort to the patient. We have therefore chosen this technique to investigate patterns of laryngeal apraxia in two patients with Broca's aphasia.

PROCEDURE

Figure 1 presents a schematic drawing of the general experimental setup. The subjects were seated in a phoniatic examination chair. A fiberscope (Olympus, ENF-P) was inserted pernasally into the pharynx, and positioned with the distal end slightly above the upper edge of the epiglottis. The cold light source used for videoendoscopic filming simultaneously acted as the light-source for registration of changes in glottal opening by means of transillumination.

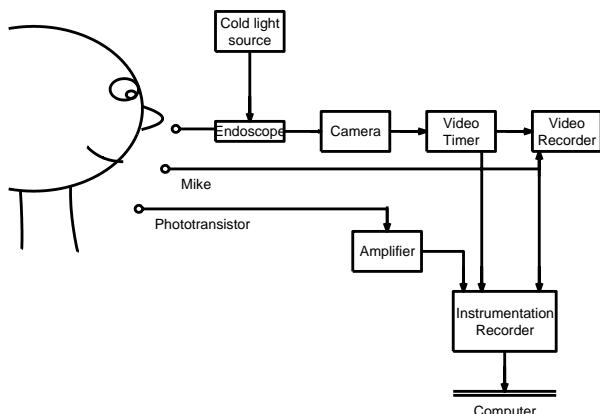


Fig. 1: Synchronized fiberoptic filming and photoelectroglottography (transillumination).

It is well known that the latter technique is susceptible to artifacts of various kinds. Particular attention was thus paid to the synchronization of the video film with the trans-

illumination signal, using a modified video timer² (cf. Fig. 1), in order to allow straightforward detection of problems due to shadowing movements of tongue root and epiglottis etc. As a second precautionary measure, two phototransistors (not shown in Fig. 1) were employed simultaneously, one positioned on the skin between cricoid and thyroid cartilage, and one below the thyroid cartilage (see Löfqvist & Yoshioka, 1980 and Hoole, in press b, for discussion of the implications of phototransistor position.) The assumption here is that disturbances of the above type will affect the two phototransistors differentially and so allow their detection.

The material recorded for each subject included isolated vowels and fricatives, diadochokinetic sequences with voiceless plosives and fricatives, as well as a series of real words, spoken in the carrier phrase *Lies 'die ...' bitte* ("Read 'the ...' please"). The latter were designed to elicit voiceless and voiced plosives and voiceless fricatives in a reasonably homogeneous context.

Typical data for a normal speaker is shown in figure 2, in which the sentence *Lies 'die Schiffe' bitte* is shown with audio waveform and the two transillumination channels. The transillumination signals show (at time 100-200ms) a smooth transition from an open position of the glottis appropriate to respiration to an adducted position appropriate for voicing of the initial /l/, with the adducted position being attained some 50ms before onset of voicing. The sequence is then marked by devoicing gestures on the voiceless sounds /s/, /ʃ/, /f/ and /t/. The amplitude of the gesture is greatest on the fricative /ʃ/ associated with the syllable bearing main stress in this utterance. The typical pattern of laryngeal-oral coordination for fricatives, such that peak glottal opening occurs approximately at mid-frication, can be readily observed. The presence or absence of vocal fold vibration accompanying the gross ab- and adductory movements of the larynx can be most clearly observed in the trace labelled PGG1, corresponding to a transducer location between thyroid and cricoid cartilage. (See Löfqvist, 1990, and Hoole, in press a, for a review of normal patterns of articulatory organisation in the devoicing gesture.)

From the methodological point of view it can be added that normally, and this is the case here, the two transillumination channels will indicate the same relative amplitude for the two consonants in /ʃfθ/, for example. If this expectation is not fulfilled this acts as an indication that larynx height may have changed during the course of the word. This can then be checked in the video film.

²FOR-A VTG-33, modified according to a technique developed by N.R Petersen at the Phonetics Laboratory of Copenhagen University

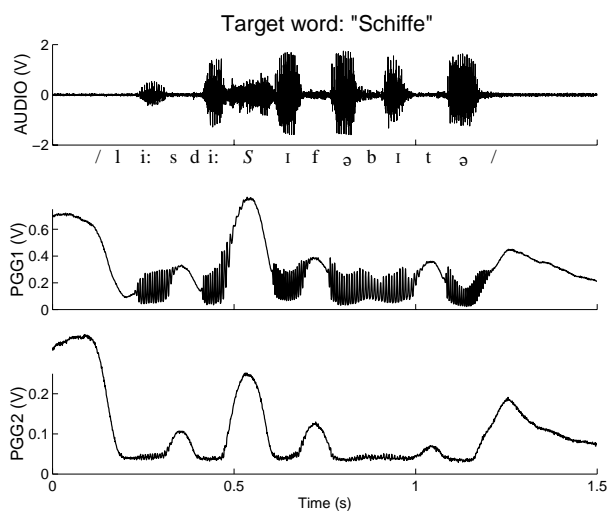


Fig. 2: Typical transillumination signals for complete sentence spoken by normal speaker. The utterance is "Lies die Schiffe bitte". From top to bottom: Audio signal; transillumination signal for phototransistor placed between thyroid and cricoid cartilage (PGG 1); transillumination signal for phototransistor placed below cricoid cartilage (PGG 2). Greater amplitude of the transillumination signals indicates more abducted configuration of the glottis.

In order to bring out the significant points more clearly the following examples only present a single low-pass filtered transillumination trace. Speech samples including artifacts were discarded.

CASE DESCRIPTIONS

We present data from two patients with Broca's aphasia. Clinical descriptions of their speech and language disturbances were obtained from the *Aachen Aphasia Test* (Huber *et al.* 1983), from an oral apraxia protocol (Kerschensteiner & Poeck, 1974) and from a repetition task including word and sentence lists that were specifically devised for examinations of patients with apraxia of speech (unpublished materials).

Patient 1

Patient 1, a 56 year old right-handed woman, suffered subtotal infarction of the left medial cerebral artery with right hemiparesis and aphasia. She was examined 3 months post-onset. Her speech was slowed and characterized by groping and false starts during the initiation of utterances and by a large number of apparent phonemic substitutions and phonetic distortions. These errors occurred on both vowels and consonants and there was no particularly high proportion of voicing errors. She spoke at a normal pitch and loudness level and had normal voice quality. In free speech the patient was agrammatic and had word finding problems. Written language and comprehension were only mildly disturbed. Patient 1 received a diagnosis of moderately severe Broca's aphasia, severe apraxia of speech and moderate oral-facial apraxia.

Patient 2

Patient 2, a right-handed woman, was 29 when she suffered intracerebral temporal hemorrhage from an aneurysm of the left medial cerebral artery and, postoperatively, a left MCA infarction. She had a right hemiparesis. The examinations reported here were obtained 9 months post-onset. At this time her speech was slow and halting and was characterized by distortions of vowels and consonants and by phonemic paraphasias. The clinical report mentioned a remarkable proportion of voicing errors. She had no groping and no particular speech initiation problems and spoke with a normal voice and at a normal pitch and loudness level. Her language production was agrammatic with word finding problems and semantic paraphasias. Comprehension was moderately disturbed. She had a severe agraphia and a deep dyslexia. A diagnosis of moderate Broca's aphasia with apraxia of speech was made. Further, a mild oral-facial apraxia was diagnosed.

OBSERVATIONS

Patient 1

Figure 3 presents an example of laryngeal impairment related to the patient's pervasive initiation problem. It shows laryngeal activity during a complete sentence (/li:s di: pəsə bɪtə/ , Read 'the passports', please).

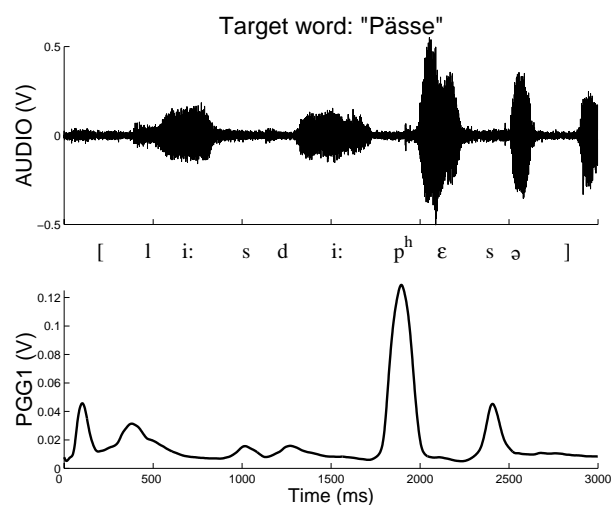


Fig. 3: Complete utterance of Patient 1; target word "Pässe". Audio waveform and low-pass filtered transillumination signal are shown.

Recalling the appearance of the normal subject shown in figure 2, the first point to notice here is that the patient had clear problems in performing the initial adductory gesture. There was no smooth transition from respiratory to phonatory position. At the left edge of the figure, at $t=0$ ms, adduction has already taken place, but voice-onset for the utterance does not occur until much later, at about $t=300$ ms. Moreover, between times 0 and 300 ms, two anomalous abductory movements can be observed. These observations reflect consistent features of her utterance-initial behaviour, which, it

might be noted, were not generally accompanied by audible output. Once the utterance was initiated, however, the patient often seemed capable of producing devoicing gestures of normal amplitude, velocity and timing. Thus, as with the normal speaker in Fig. 2, the devoicing gesture of greatest amplitude is found on the linguistically important syllable carrying main sentence stress, in this case the /p/ of "Pässe" (at around t=1800ms). The timing with respect to the oral articulation is also appropriate, with peak glottal opening occurring at about the time of release of the oral occlusion, resulting in a /p/ with an appropriate degree of aspiration for German.

In contrast figure 4 gives an example of a "false start" or initiation problem not at the level of the whole utterance but at the level of a single sound. The patient appears to have difficulty assembling the constituent gestures for the desired sound. The target word to be elicited was /dɛlɐ/; the figure shows the end of the definite article "die", followed by the initial consonant and the stressed vowel of the target word. The patient obviously made an initial abortive attempt roughly transcribed as [ve] in which the oral articulation was inappropriate whereas the very restricted glottal gesture would probably be acceptable for the target /d/ (between t=250 and t=450ms). At the second attempt the patient produced a very clear [t^h] (at around t=550ms), the oral articulation now being correct and the laryngeal one completely wrong, i.e clearly showing the amplitude and timing characteristics appropriate for a voiceless aspirated plosive. The result is thus a voiced-to-voiceless substitution. It cannot be excluded that this problem was triggered by an effect of lexical interference or phonemic perseverence, since shortly beforehand the rather similar word "Teller" (which has initial voiceless /t/) had been elicited.

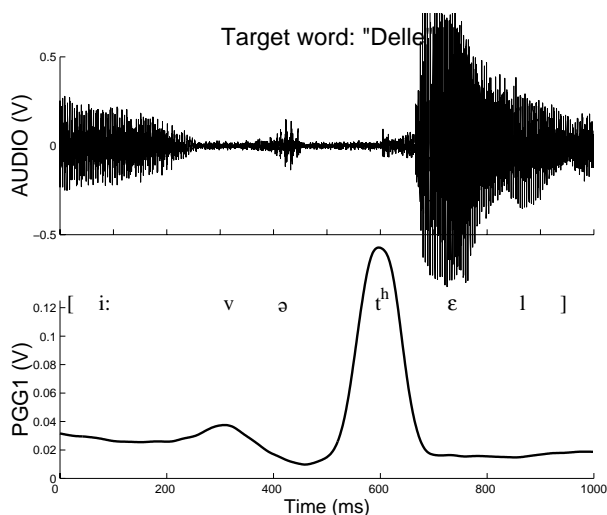


Fig. 4: Patient 1. Detailed view of realization of initial voiced consonant in the target word "Delle".

Two further examples of aberrant laryngeal movements are to be found in figures 5 and 6, both involving voiceless fricatives. In figure 5 the target word was /fɛ:dɐ/ (*feather*) and the figure shows in detail the initial /f/. Again, part of the

preceding definite article and the following stressed vowel /e:/ are shown. The laryngeal movement was defective in two respects. Firstly, the double-peaked pattern (between t=300 and t=600ms) is most unusual for a singleton consonant (the literature provides many examples where sequences of two, or occasionally even more voiceless consonants are characterized by only a single-peaked devoicing movement; see Hoole, in press a, for review). This might have had no very obvious acoustic consequences. However, the final adductory phase was completed too late so that the initial portion of the /e:/ was unnaturally breathy, indicated here by the lower amplitude of voicing in the audio waveform at around t=550 to 600ms.

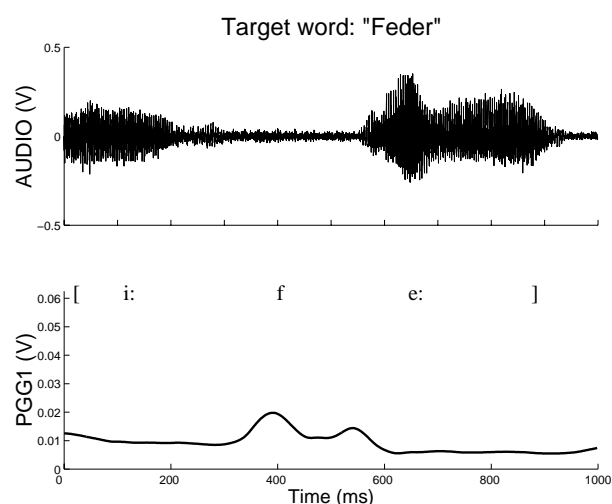


Fig. 5: Patient 1. Example of aberrant laryngeal movements in fricative production. Detailed view of initial /f/ in the target word "Feder"

Finally, in figure 6, in which the target word is /fɪʃ/ (*fish*), the initial /f/ is also marked by aberrant articulatory behaviour. At the laryngeal level, the initiation of glottal abduction for /f/ (at around t=400ms) occurs very late with respect to the end of the previous /i:/. (Compare with the /i:/ to /f/ transition at around t=450ms for the normal speaker in the PGG2 trace in Fig.2.) Thus, there again appears to be a lack of fluency in managing articulatory transitions. In this particular case it may be suspected that this lack of fluency is present at the oral level, too, i.e in the formation of the labiodental constriction, as indicated by a short increase in the amplitude of the audio waveform in the middle of the main closure phase (at around t=400ms). The amplitude of the devoicing gesture for /f/ may also be rather weak in this case, since the following /ʃ/, in more weakly stressed position, has a greater amplitude of devoicing. (Contrast this with the pattern seen for the target word of the normal speaker in Fig.2 between t=450 and t=800ms.)

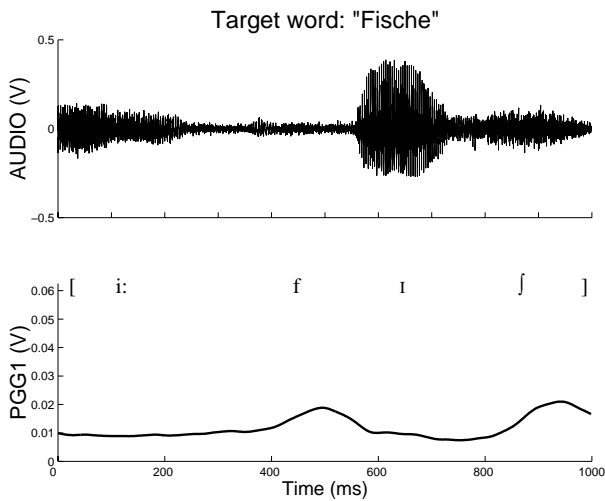


Fig. 6: Patient 1. Detailed view of initial /f/ in the target word "Fische"

Patient 2

Due to a severe problem in verbal repetition the second patient usually proved unable to repeat the complete sentence, so that in our examination we normally only attempted to elicit the target word itself, without the carrier phrase. However, it should be recalled here that, unlike the first patient, patient 2 did not have any clinically obvious initiation problems. Thus in figure 7, which shows two repetitions of the word /pɛsə/ (*passports*), the transition from the abducted position for respiration to adducted position for the first vowel is fluently managed. It exhibits the appropriate abductory movement (at around t=150ms in both examples) associated with the initial aspirated /p/ overlaid on the overall closing movement (the movement pattern is thus somewhat different from that seen for the utterance spoken by the normal speaker in figure 2, between t=100 and t=200ms, where the initial sound is voiced).

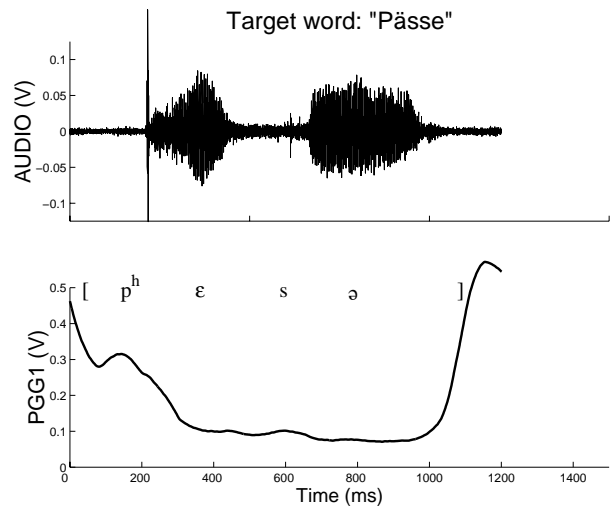
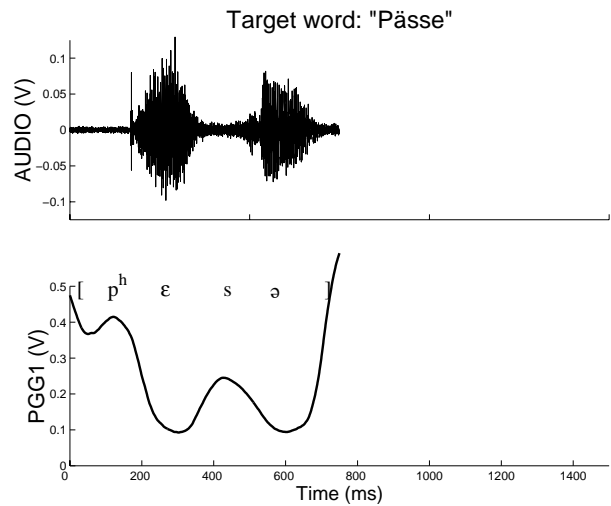


Fig. 7: Patient 2. Two repetitions of the word "Pässe". Each word spoken in isolation (top: 1st repetition; bottom: 2nd repetition).

The point of interest in this figure is that the amplitude of the devoicing gesture of the medial /s/ is inconsistent in the two examples, with a gesture of normal rate and extent in the upper panel (at around t=540ms) and a substantially smaller one in the lower panel (at around t=600ms). Whether, in the low-amplitude case, this really represented a movement that would have been typical for a production of the voiced cognate is somewhat doubtful. Both fricatives were acoustically voiceless, but showed only weak friction energy (overall, this patient tended to speak at an acceptable, but nonetheless rather quiet sound pressure level). Inconsistency is a frequently cited characteristic of apraxic disturbances, and can conceivably arise at different levels of the speech production system. In this particular case, there is no obvious way to decide whether the repetitions reflect inconsistency at the purely motor execution level (in movement amplitude) or inconsistency at a higher level of motor planning and sound selection, i.e. the correct sound is chosen in the first case but

not in the second. We should note that if the second (low-amplitude) repetition does represent an error at the planning level, then it falls into a different category of phonological error from those shown elsewhere in this paper (Fig.4; see also Fig. 9 below) since voiced fricatives cannot occur in this context in German. It would thus involve a phonotactic violation rather than a simple error of phoneme selection.

We turn now to a different kind of example, which is shown in Fig. 8. The target word is /bɛsə/ (*basses*). Recalling the course of the adduction for the initial /p/ of /pɛsə/ (figure 7) we see here that the patient quite correctly performed a qualitatively different gesture lacking the small devoicing gesture associated with the voiceless /p/ (the trajectory is thus similar to that seen at the onset of the normal speaker's utterance in figure 2, with a simple monotonic falling pattern over roughly 100ms preceding utterance onset). Unfortunately, the timing here was not quite correct, adduction being completed too late. Thus the /b/ became somewhat aspirated - about 25 ms - which was in fact enough to push it into a phonemically different voicing category. It is important to note here that a correct interpretation of this error (i.e. it is not an error of phoneme selection) only becomes possible through instrumental techniques, such as the one employed here, making the laryngeal kinematic information available.

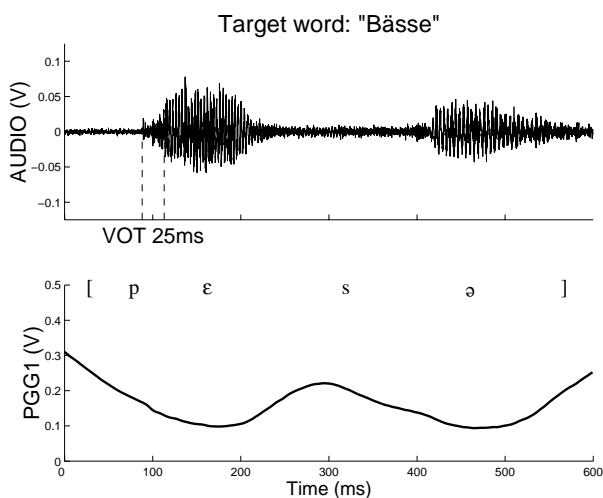


Fig. 8: Patient 2. Detailed view of the target word "Bässe" (spoken in isolation), showing discoordination of oral and laryngeal movements for the initial /b/. Duration of voice onset time is indicated.

Finally, figure 9 illustrates a case where a straightforward phonemic error does seem to occur. Here the patient managed to pronounce the target word together with the definite article i.e. "die Pässe". The initial consonant should thus have been a voiced /d/ (or one with short voicing lag), with the shape of the adduction gesture prior to utterance onset being similar to the one seen in figure 8 (or the onset of the utterance in figure 2). However, it was produced with the typical trajectory for a voiceless plosive (such as that seen for the initial /p/ in the two repetitions of figure 7). The resulting VOT was in the typical range of German voiceless plosives. What might have

triggered this apparent phonemic error? In this utterance the biphasic pattern of laryngeal abductions that would have been expected (corresponding to the two voiceless consonants /p/ and /s/) is substituted by a triphasic one which is in synchrony with the syllabic rhythm of the utterance. Moreover, the devoicing on the true voiceless consonants (at t=600 and t=900ms for /p/ and /s/, respectively) was actually rather more vigorous than in many of the patient's other utterances. One could then speculate that a process of conformation to syllabic homogeneity, steered by the syllable with main stress, was responsible for the inappropriate devoicing of /d/.

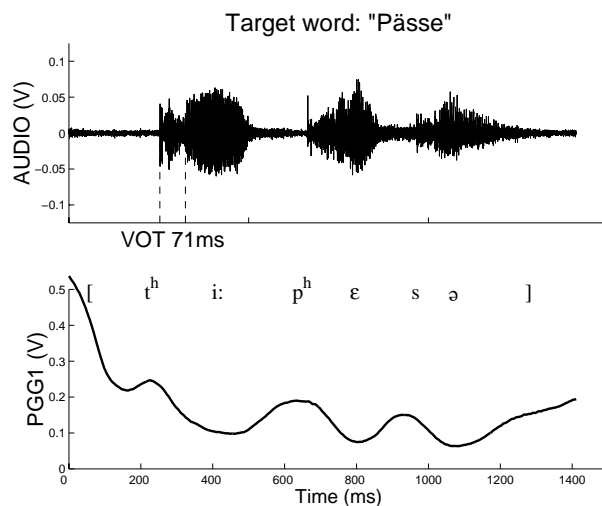


Fig. 9: Patient 2. Incorrect devoicing gesture on the initial /d/ of the phrase "die Pässe". Duration of voice onset time is indicated.

DISCUSSION

The observations communicated here focussed on laryngeal movements in apraxia of speech.

In part, the laryngeal signs described for the two patients were compatible with their clinical appearance. The groping behavior of patient 1, for instance, was also visible at the laryngeal level, showing up in *conduite d'approche*-like adductions or in trial-and-error attempts at certain patterns of laryngeal-articulatory coordination (figures 3 and 4). In patient 2, who was more fluent on the clinical surface, these laryngeal patterns were not present.

In all aspects of their laryngeal movement disturbances the two patients showed inconsistent behavior, in the sense that a gesture which was disturbed in one instance could be performed completely normally in another (cf. figure 7). The source of this variation is unknown, but this behavior is characteristic of apraxic disorders and provides a diagnostic criterion to discriminate apraxia of speech from the dysarthrias (Buckingham, 1991).

Beyond this, some of the observations tentatively reported here may add new evidence to our understanding of the mechanisms underlying phonetic distortions and phonemic substitutions in apraxic speech. There were, on the one hand,

instances of altered movement shape in laryngeal abductions, e.g. double-peaked movements or aberrant movement amplitudes, leading to phonetic distortions of the target sound (figures 5, 6, 7). On the other hand, disturbed timing of laryngeal ab- or adduction was identified as a source of both phonetic and phonemic errors (figures 5, 6, 8). The quality of the resulting errors, phonetic or phonemic, seemed to depend mainly on the quantitative aspects of the underlying motor problem. From the point of view of the laryngeal movement pattern, a distinction between phonetic and phonemic errors may be somewhat artificial in these cases (for a discussion of this point cf. (Ziegler, 1987; Ziegler & Hoole, 1989). In other instances, errors surfacing as phoneme substitutions were associated with a categorically deviant laryngeal gesture, e.g. a clear abduction where a smooth adductory gesture (figure 9) or a maintenance of an adducted posture (figure 4) would have been expected. The location of the origin of these errors along the chain of phonological encoding processes is less clear, although a dysfunction at some categorical level of gestural or segmental implementation must be involved (Butterworth, 1992). In both normal and aphasic speech segmental errors of this kind are frequently triggered by contextual influences, e.g. anticipations, perseverations, or metatheses (cf. Meyer (1992) for a discussion of such errors in normal speakers). Figure 9 presents an example of an anticipatory error, more specifically an anticipation of the feature "voiceless". One might speculate here that the control of the devoicing gestures within the three-syllabic utterance "die Pässe" is not only governed locally, but is also integrated into a serial process governing the rhythmically organized sequence of speech gestures that makes up this particular syllabic chain. A model of this kind, characterized by the metaphor of "(syllabic) frame and (segmental) content", has been proposed as an explanation of speech acquisition mechanisms (e.g. Davis & McNeilage, 1995). In apraxic speakers, the gestural composition of syllabic chains might, as a consequence of a lesion to the relevant premotor area of the left hemisphere, have disintegrated. This would in turn result in a "harmonization" of the pattern of devoicing gestures with the global syllabic rhythm of an utterance (figure 9) or in trial-and-error attempts at combining the gestural building blocks of an utterance (figures 3, 4). Thus, a single pathomechanism of gestural disintegration might account for apparently rather distinct error types.

Although we have proposed some tentative interpretations of the findings presented here, caution should still be exercised due to the small number of observations. Nevertheless, the method described in this study, together with existing hypotheses concerning the control of laryngeal gestures in the articulation of voiced and voiceless consonants (Hoole, in press a), might constitute a suitable framework for future investigations of apraxic laryngeal movements.

REFERENCES

BLUMSTEIN, S., COOPER, W., GOODGLASS, H. STATLENDER, S. & GOTTLIEB, J. (1980) Production deficits in aphasia: A Voice-onset time analysis. *Brain and*

Language, **9**, 153-170.

BUCKINGHAM, H. (1991) Explanations for the concept of apraxia of speech. In M.T. Sarno (Ed), *Acquired Aphasia. 2nd edition* (San Diego: Academic Press).

BUTTERWORTH, B. (1992) Disorders of phonological encoding. *Cognition* **42**, 261-286.

DAVIS, B.L. and MACNEILAGE, P.F. (1995) The articulatory basis of babbling. *Journal of Speech and Hearing Research*, **38**: 1199-1211

DANLY, M. & SHAPIRO, B. (1982). "Speech Prosody in Broca's aphasia", *Brain and Language*, **16**, 171-190.

GANDOUR, J., PETTY, S.H., & DARDARANANDA, R. (1989) Dysprosody in Broca's aphasia: A case study. *Brain and Language*, **37**, 232-257.

GANDOUR, J., POTISUK, S., PONGLORPISIT, S., DECHONGIT, S., KHUNADORN, F. & BOONGIRD, P. (1996) Tonal coarticulation in Thai after unilateral brain damage. *Brain and Language*, **52**, 505-535.

GROSWASSER, Z., KORN, C., GROSWASSER-REIDER, I. and SOLZI, P. (1988) Mutism associated with buccofacial apraxia and bihemispheric lesions. *Brain and Language* **34**, 157-168.

HEESCHEN, C., RYALLS, J. and HAGOORT, P. (1988) Psychological stress in Broca's versus Wernicke's aphasia. *Clinical Linguistics and Phonetics* **2**, 309-316.

HOIT-DALGAARD, J., MURRAY, T. & KOPP, H. (1983) Voice onset time production and perception in apraxic subjects. *Brain and Language*, **20**, 329-339.

HOOLE, P. (in press, a) "Laryngeal Coarticulation. Section 1: Coarticulatory investigations of the devoicing gesture". In: W.H Hardcastle and N. Hewlett (eds.), *Coarticulation: Theoretical and Empirical Perspectives*. (Cambridge University Press).

HOOLE, P. (in press, b) "Laryngeal investigative techniques. Section 1: Investigation of the devoicing gesture. In: W.H Hardcastle and N. Hewlett (eds.), *Coarticulation: Theoretical and Empirical Perspectives*. (Cambridge University Press).

HUBER, W., POECK, K., WENIGER, D. and WILLMES, K. (1983) *Aachener Aphasie Test*. (Göttingen: Hogrefe).

ITOH, M., SASANUMA, S., TATSUMI, I. F., MURAKAMI, S., FUKUSAKO, Y. and SUZUKI, T. (1982) Voice onset time characteristics in apraxia of speech. *Brain and Language* **17**, 193-210.

KERSCHENSTEINER, M. and POECK, K. (1974) Bewegungsanalyse bei buccofacialer Apraxie. *Der Nervenarzt* **45**, 9-15.

KONNO, K., SUGISHITA, M. and HIROSE, H. (1987) Articulatory movements in apraxia of speech. *Annual Bulletin of the Research Institute of Logopaedics and Phoniatrics* **21**, 177-192.

LÖFQVIST, A. and YOSHIOKA, H. (1980) Laryngeal activity in Swedish obstruent clusters. *Journal of the Acoustical Society of America* **68**, 792-797.

LÖFQVIST, A. (1990) Speech as audible gestures. In W.J.

Hardcastle and A. Marchal (eds.) *Speech Production and Speech Modelling*, pp. 289/322. (Dordrecht: Kluwer Academic Publishers).

MEYER, A.S. (1992) Investigation of phonological encoding through speech error analyses: Achievements, limitations, and alternatives. *Cognition* **42**, 181-211.

ODELL, K., MCNEIL, M., ROSENBEK, J. C. and HUNTER, L. (1990) Perceptual characteristics of consonant production by apraxic speakers. *Journal of Speech and Hearing Disorders* **55**, 345-359.

PINEDA, D. and ARDILA, A. (1992) Lasting mutism with buccofacial apraxia. *Aphasiology* **6**, 285-292.

RUFF, R. L. and ARBIT, E. (1981) Aphemia resulting from a left frontal hematoma. *Neurology* **31**, 353-356.

RYALLS, J. H. (1984) Some acoustic aspects of fundamental frequency of CVC utterances in aphasia. *Phonetica* **41**, 103-111.

Ryalls, J. & Scarfone, D. (1990) Some preliminary observations of voice characteristics in Broca's aphasia. *J. Neurolinguistics*, **5**, 285-293.

ZIEGLER, W. (1987) Phonetic realization of phonological contrast in aphasic patients. In J.H. Ryalls (Ed), *Phonetic Approaches to Speech Production in Aphasia and Related Disorders*. (Boston: College Hill Press).

ZIEGLER, W. and ACKERMANN, H. (1994) Mutismus und Aphasie - eine Literaturübersicht. *Fortschritte der Neurologie - Psychiatrie* **62**, 366-371.

ZIEGLER, W. and HOOLE, P. (1989) A combined acoustic and perceptual analysis of the tense-lax opposition in aphasic vowel production. *Aphasiology* **3**, 449-463.