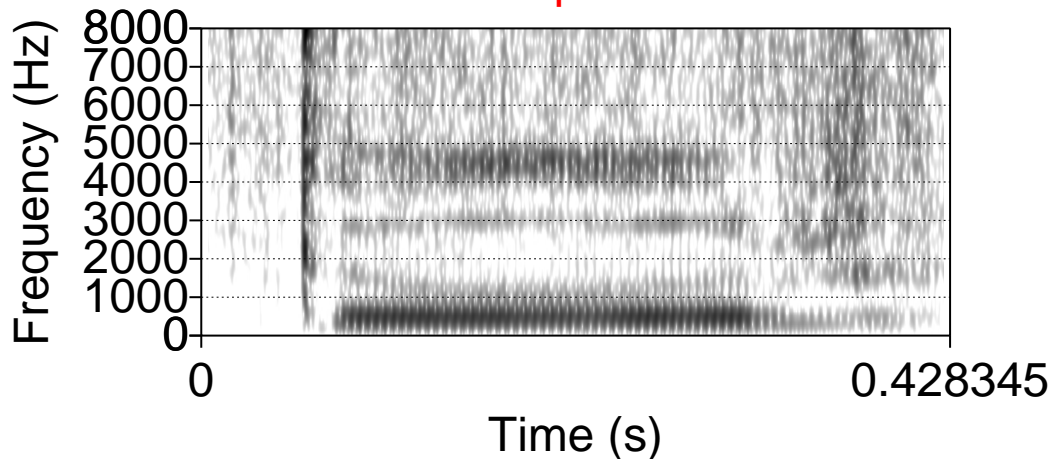


### Temne. Apical Dental



### Temne. Laminal Alveolar

