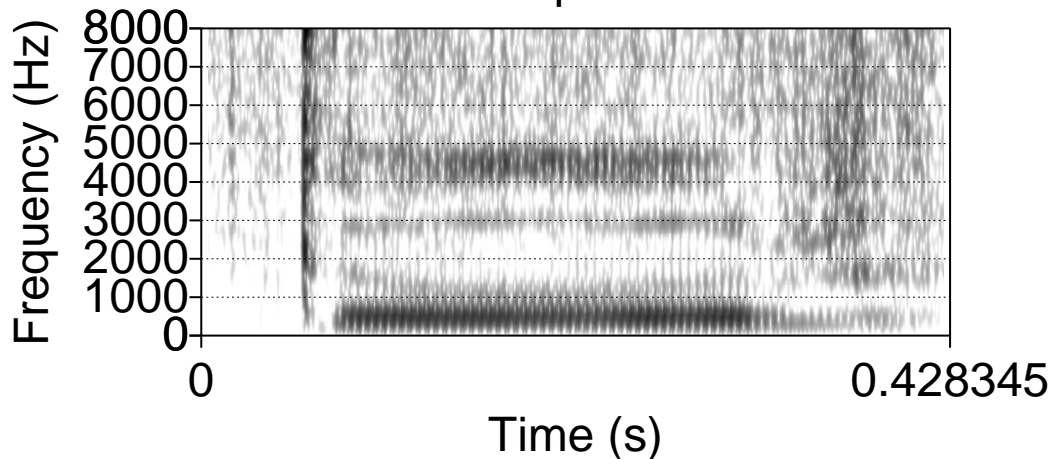


Temne. Apical Dental



Temne. Laminal Alveolar

