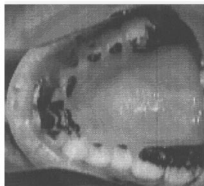


(e)



(f)

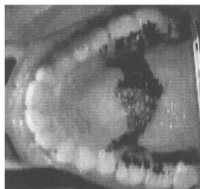


FIG. 1. (a) Midsagittal MR image for [l] (b) Midsagittal MR image for [ɭ]. (c) 3-D tongue shape for [l]. The 3-D tongue is viewed from the side [refer to the view orientation arrow shown in the midsagittal image of panel (a)] and tilted toward the front for better display. The tongue tip appears toward the lower right of the panel. (d) 3-D tongue shape for [ɭ]. The 3-D tongue is viewed from the posterior pharyngeal wall [refer to the view orientation arrow shown in the midsagittal image of panel (b)] and given a forward tilt of 35° for a better view. The tongue tip is toward the top of the panel. (e) Linguopalatal contact for [l], dark region is area of contact, front of mouth is toward the left. (f) Linguopalatal contact for [ɭ] (dark region is area of contact, front of mouth is toward the left).