

Extrinsic and intrinsic muscles of the tongue

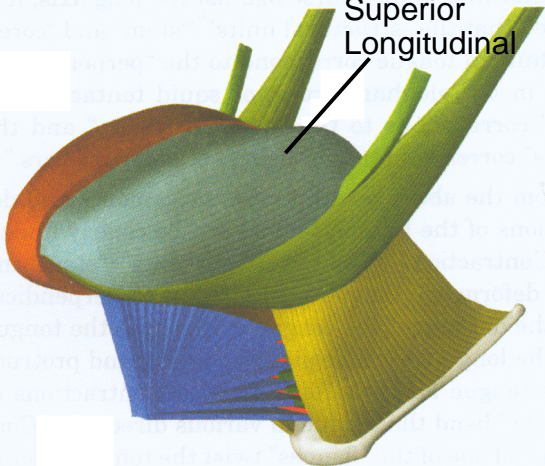
Three-dimensional schemata of the tongue musculature based on dissection and histologic data.

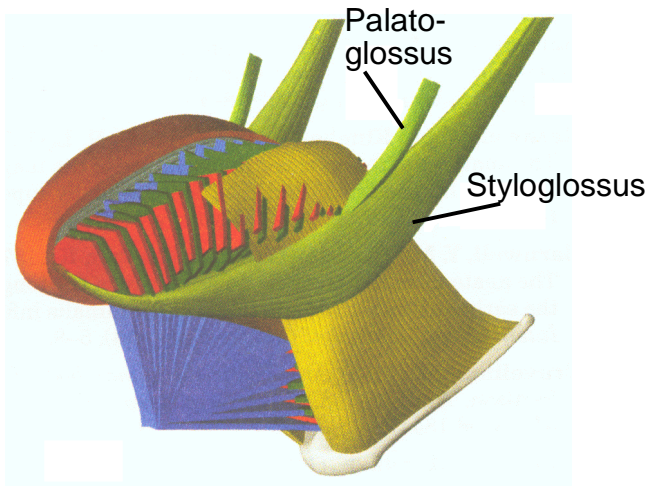
Figs. 9 and 10a-d from Takemoto (2001), JSLHR 44(1), 95-107.

The figures are ordered from outer to inner musculature.

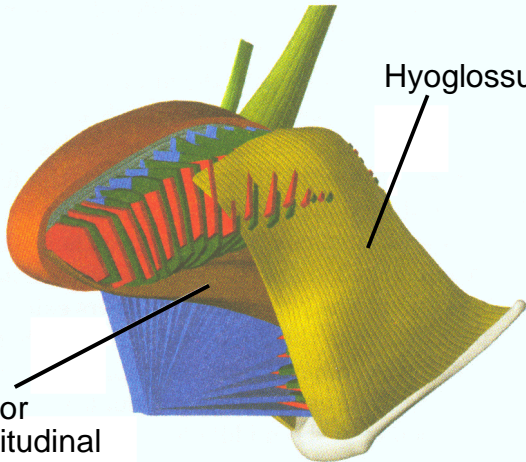
Note in particular the layered structure (“lamina”) of Genioglossus, Transversus and Verticalis.

Superior
Longitudinal

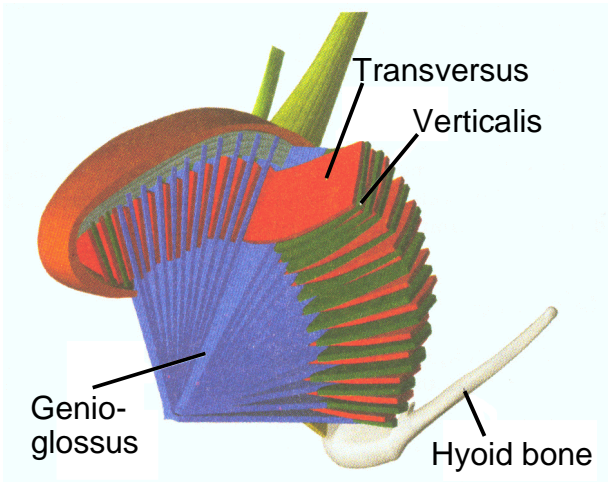




Hyoglossus



Inferior
Longitudinal



fringe (Palatoglossus)

fringe
(Styloglossus)

mucous
membrane

Transversus

Verticalis

fringe
(Hyoglossus)

Genioglossus

Longitudinal
fibres (cover)

